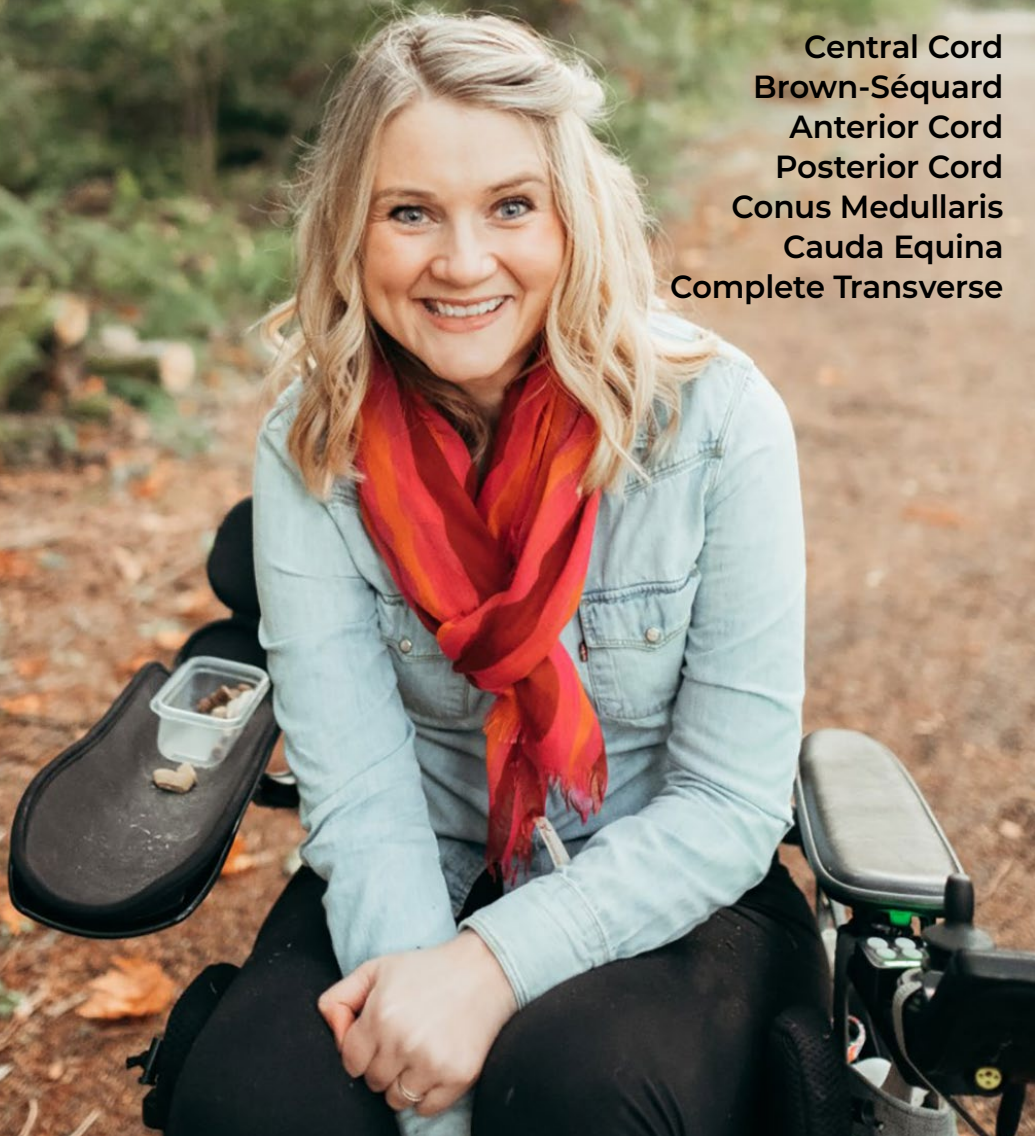

LIVING WITH PARALYSIS

Spinal Cord Syndromes:

Central Cord
Brown-Séquard
Anterior Cord
Posterior Cord
Conus Medullaris
Cauda Equina
Complete Transverse



CHRISTOPHER & DANA
REEVE FOUNDATION

TODAY'S CARE. TOMORROW'S CURE.®

© 2026 Christopher & Dana Reeve Foundation

This guide has been prepared based on scientific and professional literature. It is presented for the purpose of education and information; it should not be construed as medical diagnosis or treatment advice. Please consult a physician or appropriate healthcare provider for questions specific to your situation.

Credits:

Written by: Liz Leyden

Editorial Consultant: Linda M. Schultz, PhD, CRRN

Illustrations by: Miguel A. Najarro

Photos: Courtesy of Jessie Owen

Christopher & Dana Reeve Foundation

636 Morris Turnpike, Suite 3A

Short Hills, NJ 07078

(800) 539-7309 toll free

(973) 379-2690 phone

ChristopherReeve.org

LIVING WITH PARALYSIS

Spinal Cord Syndromes

Introduction	4
Anatomy of the Spinal Cord	5
How Injuries Occur	6
Central Cord Syndrome	7
Jessie Owen Story	9
Brown-Séquard Syndrome	11
Anterior Cord Syndrome	13
Posterior Cord Syndrome	14
Conus Medullaris Syndrome	15
Cauda Equina Syndrome	16
Complete Transverse Syndrome	17
Support and Sources	19



CHRISTOPHER & DANA
REEVE FOUNDATION
TODAY'S CARE. TOMORROW'S CURE.®

INTRODUCTION

The spinal cord is a critical communication center that links the body and brain, facilitating movement, relaying sensory information, and regulating major functions such as bowel and bladder, digestion, and heart rate.

Complete spinal cord injuries affect an entire spinal cord segment, resulting in total functional loss below the level of injury. Injuries damaging only part of the cord's nervous tissue are classified as incomplete spinal cord syndromes because they leave some level of sensory and motor function intact.

Incomplete spinal cord syndromes include central cord syndrome, Brown-Séquard syndrome, anterior cord syndrome, posterior cord syndrome, and conus medullaris syndrome. Although not clinically classified as an incomplete spinal cord syndrome, cauda equina syndrome is a neurological disorder caused by impairment to the spinal cord that shares similar symptoms with conus medullaris syndrome.

These syndromes occur when trauma or chronic disease damage the nerve tissue in the ascending and descending spinal tracts, or the nerve roots at the bottom of the spinal canal. Ascending spinal tracts convey messages up to the brain about sensation, including pain, temperature, fine touch and proprioception (an awareness of the position and movement of the body.) Descending spinal tracts carry messages about voluntary movement, posture, balance, muscle tone, and reflexes down the cord.

Disrupted pathways can cause a range of functional loss, including weakness or partial paralysis, diminished sensation and sexual function, and bowel and bladder dysfunction. The severity of impairment will vary depending on the size and location of the lesion.

Individuals diagnosed with an incomplete spinal cord syndrome can expect their medical team to focus on treating the cause of the lesion and preventing further damage to the cord. Injuries, whether a result of trauma or disease, may require surgery to stabilize or relieve cord compression. Acute care will be followed with physical and occupational therapy to support recovery of function.

ANATOMY OF THE SPINAL CORD

To understand the potential effects of incomplete spinal cord syndromes, it helps to define and visualize how the spinal cord corresponds with specific parts of the body.

The spinal cord is a bundle of nerves that begins at the base of the skull and descends roughly 18 inches down the back through a hollow opening in the spine known as the spinal canal. The small, stacked bones (vertebrae) that comprise the spine not only act as a structural support for the body, but also protect the cord and its crucial role in communication. Intervertebral discs between the vertebrae prevent the bones from rubbing together and absorb shocks. Any of these bones may be broken without causing a spinal cord injury if the cord itself remains undamaged. Conversely, a spinal cord injury may occur absent any broken bones, caused instead by bruising or compression of the cord.

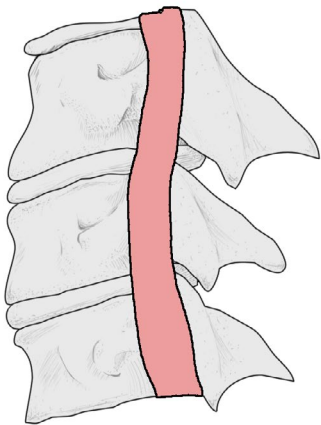


Figure 1A: Normal Vertebra

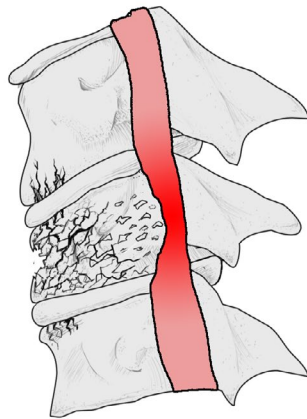


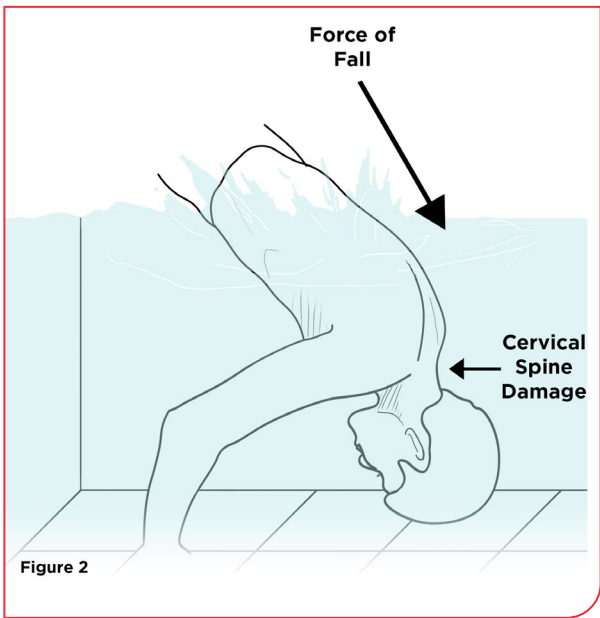
Figure 1B: Damaged Vertebra

The spine is divided into four sections: cervical, thoracic, lumbar, and sacral. Nerves in the cervical region (C1-C7) control signals to the neck, arms, and hands. The thoracic region (T1-T12), or upper back, relays signals to the torso and parts of the arms. The spinal cord ends at the top of the lumbar, or lower, spine (L1-L5) whose vertebrae are larger than any other section to sustain the weight of the spine; this region controls the hips and legs. The sacral spine (S1-S5) is made up of five vertebrae fused

into a triangular shape between the lumbar spine and tailbone; nerve roots extending from the bottom of the spinal cord continue through the sacral region, affecting the lower trunk and legs, as well as bowel and bladder and sexual function.

Nerves inside the spinal cord carrying messages from the brain exit the spine through nerve roots between each vertebra. Damaged nerve fibers branching off these vertebrae can impair function related to muscles and nerves throughout the body. The location of a spinal cord injury determines what part of the body and functions are affected. For example, an L3 injury will impair an individual's ability to straighten the knees, while an injury to the S1 nerves will cause deficits in the hips and groin area.

HOW INJURIES OCCUR



The spine is capable of all kinds of movement, including bending forward or from side to side; twisting at the waist and turning the neck; and stretching backward with the head tilted toward the sky.

Injury causing events, from falls or car accidents or gun violence, can force the body into extreme positions

and cause the same bones that protect the spinal cord to damage it. Some mechanisms of injury commonly associated with incomplete spinal cord syndromes include hyperextension and hyperflexion injuries. A hyperextension injury is caused when the head is forcefully snapped backwards, while a hyperflexion injury thrusts the chin sharply toward the chest.

Fractures, whether caused by trauma or disease-related factors such as tumors or herniated discs, can range from mild to severe depending on the angle and force of injury, and any resulting instability in the spine. Burst fractures are typically the most serious, occurring when a vertebra is shattered; this injury cannot only destabilize the spine, but potentially cause splintered fragments of bone to pierce or compress the spinal cord.

Preexisting conditions that weaken bones also play a major role in increasing an individual's susceptibility to incomplete spinal cord injuries. Spinal conditions associated with the wear and tear of aging, including osteoarthritis or degenerative disc disease, frequently cause severe compression of the spinal cord and nerve roots over time. These chronic, slow-motion injuries can cause incomplete spinal cord syndromes, and also contribute to cord compression caused by traumatic injury.

CENTRAL CORD SYNDROME

Central Cord Syndrome is characterized by weakness and impaired function affecting the arms and hands more so than the legs. This condition, the most common type of incomplete spinal cord syndrome, is caused by damage to the central part of the cervical spinal cord which contains nerves that control the movement of the arms and hands. Because the nerves that control the legs are located toward the outside of the cord, and therefore typically beyond the scope of the injury, the function of lower limbs is less affected. Among younger individuals, central cord syndrome may be the result of an injury due to trauma (such as when the head snaps backwards after hitting the chin on a downward fall.) The syndrome commonly occurs in people over the age of 50 in conjunction with an underlying weakness in the spine caused by osteoarthritis; this degenerative condition causes the vertebral bones to narrow the spinal canal, exacerbating the compression of the spinal cord from disc herniation or when the neck is hyperextended. No matter the mechanism of injury, the level and type of functional loss depends on the degree of nerve damage.

Symptoms:

- **Paralysis or loss of fine motor skills in the arms and hands**
- **Some weakness or impairment in the legs**
- **Some loss of sensation below the level of injury**
- **Dysfunction of the bowel and bladder**
- **Tingling, burning, or dull ache**

Figure 3A depicts the parts of the body affected by central cord syndrome. Figure 3B depicts a cross section of a spinal cord affected by central cord syndrome.

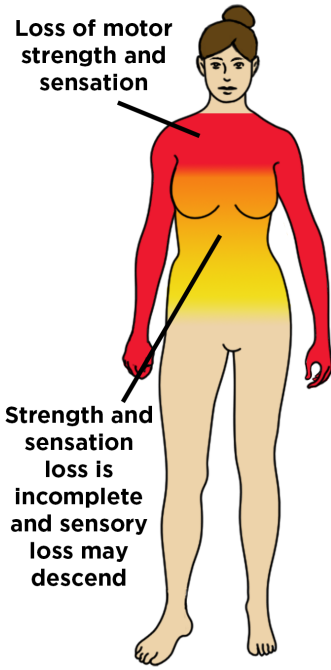


Figure 3A

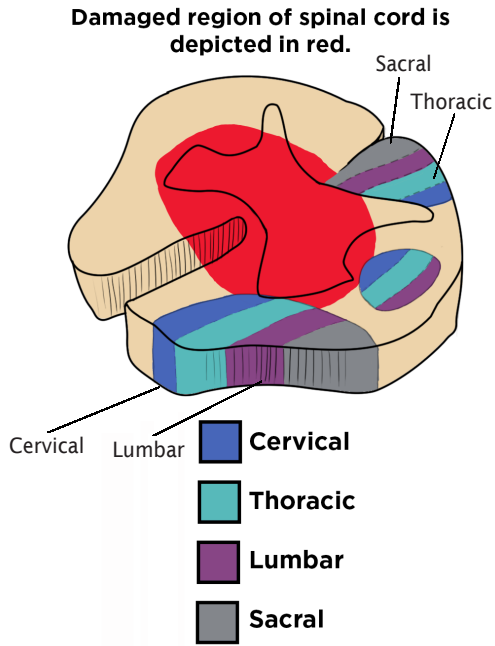


Figure 3B

Diagnosis:

Doctors will assess a patient's medical history and conduct a general and neurological examination to evaluate symptoms. Magnetic resonance imaging (MRI) or computed tomography (CT) scans and cervical spine X-rays (if MRI is unavailable) will be used to determine the level of compression and instability within the spine.

Treatment:

Spinal instability or disc herniation is often treated with surgery to prevent additional damage; surgery may also eventually be needed to address osteoarthritis or degeneration that is causing the spinal cord to narrow and compress. Physical and occupational therapy will follow acute treatment.



When her exercise therapists suggested that Jessie Owen try to put weight on her legs, she thought they were crazy.

“I was like, ‘No, I’m paralyzed. You guys don’t understand,’” she says. But before she knew it, they were lifting her up and Owen was shocked to find herself briefly standing on her own.

“I knew then that something was really different about my injury,” she says.

Owen had sustained a C3-C4 spinal cord injury five months earlier, in December 2012, when a tree fell on her family’s car during a snowstorm. The damage to her spinal tract resulted in central cord syndrome, a condition that weakens or paralyzes hands and arms more so than the lower limbs. But the possibility that her legs might regain lost function wasn’t clear to Owen until that moment.

For the next couple years, she embarked on an intensive exercise program to capture as many gains as she could. Working out four times a week, Owen strengthened her legs and core muscles to the point that she was able to rise from a seated position without using her arms. She progressed from standing to taking steps with a walker and, eventually, with crutches.

“What all of this did was give me confidence to start trying out new, independent things for myself,” she says.

But even as Owen achieved new milestones, including driving again with help from an adaptive knob fixed to the steering wheel, the fact that her leg muscles worked better than her arms and hands was deeply frustrating.

“I was having trouble cooking and dressing and showering, and it became a little bit of a mental battle to figure out why I could do this and not that,” she says. “I struggled with why my legs were so much stronger. I wondered if people could see me stand but then I can’t use my arms, do they think I’m faking?”

The rarity of central cord syndrome—“I’ve never met anyone quite like me”—combined with the condition’s characteristic upper extremity weakness, challenged Owen’s sense of recovery. The gains she’d had in her lower limbs sometimes seemed less important than being able to button her shirts or handle classroom materials in her work as an elementary school teacher.

“The grass is always greener,” she says.

Over time, and with the support of family, friends and the paralysis community, Owen adjusted to the lost function in her arms and hands. Adaptations such as button-hook tools, back scratchers, jar openers, and a chin-controlled joystick for the computer, helped Owen regain her sense of independence and press forward with her life.

“You sort of need to find your place in your own story again,” she says. “Everyone knows what it means to have your story shift unexpectedly and to completely change your perspective on the future and what you perceive is or isn’t possible. I had to come to terms with what my life looked like if my fingers weren’t coming around.”

In 2018, Owen volunteered for *a study of noninvasive electrical stimulation at the Center for Neurotechnology* at the University of Washington. Her motivation was less about actually gaining function—“I didn’t expect anything”—and more about her belief in the necessity and power of spinal cord injury research.

“I signed up for the trials because I believe if we want change and growth in the scientific community, we need to be part of it,” she says.

But after years of limited progress, the stimulation at the site of Owen's spinal cord injury increased her hand and arm strength and dexterity: she could tie her shoes and leash up her dog, cook more easily and put herself to bed. Afterwards, Owen was able to reduce her caregiving needs and move into her own home.

"The gains made a difference," she says. "Would I love more still? Yes. But anything better than what you have is a huge deal in independence and happiness, in being able to take a little better care of yourself."

Nine years after being diagnosed with a spinal cord injury, Owen is back to work part-time, married, and expecting her first child.

"After a diagnosis, it's hard to think you will ever find the happiness you had before because this disability sucks so much out of you physically and mentally," she says. "But I have found it again. And I'm really happy."

BROWN-SÉQUARD SYNDROME

This rare condition occurs when one half of the spinal cord is damaged, disrupting the pathways of many spinal tracts. The resulting lesion causes partial paralysis and an impaired sense of touch, position and vibration on the same side of the body as the cord damage, and a loss of pain and temperature sensation on the opposite side. Violent trauma— including gunshots or puncture wounds to the neck or back— is the most common cause of this condition, but Brown-Séquad Syndrome can also be the result of damage caused by a herniated disk, tumor, or blocked blood vessel.

Symptoms:

- **Partial paralysis or weakness on the same side of the body as the lesion, beginning below the level of injury**
- **Loss of pain and temperature sensation on the opposite side of the body, beginning below the level of injury**
- **Decreased levels of touch, vibration and proprioception (awareness of position and movement) on same side as injury**
- **Possible bowel and bladder dysfunction**

Figure 4A depicts the parts of the body affected by Brown-Séquard syndrome. Figure 4B depicts a cross section of a spinal cord affected by Brown-Séquard syndrome.

The side of the body that has spinal cord damage loses voluntary motor control.

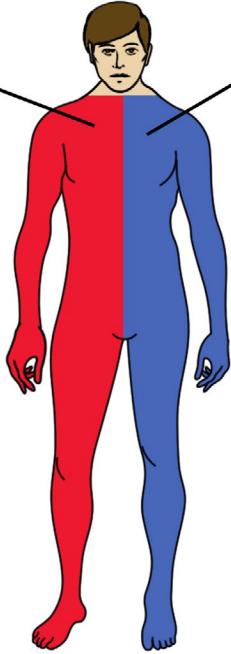
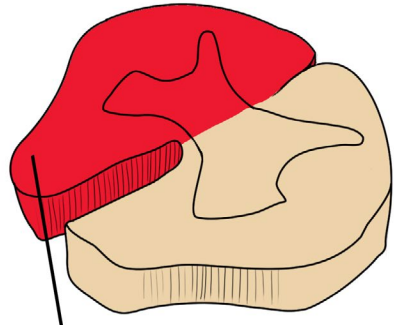


Figure 4A

The side opposite of the damaged cord has a loss of pain and temperature awareness.



Damaged region of spinal cord is depicted in red.

Figure 4B

Diagnosis:

An MRI or X-ray can help identify damage to the spine. A clinical examination of symptoms will help distinguish Brown-Séquard from other syndromes and diseases such as stroke or multiple sclerosis.

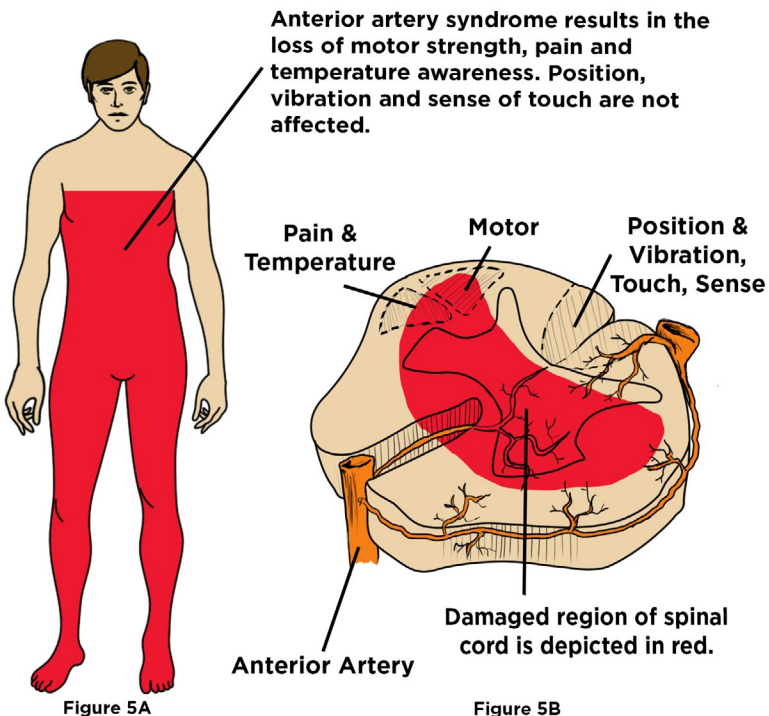
Treatment:

Treatment varies depending on the cause of the injury. Surgery may be required to relieve compression or stabilize the spine, or to repair traumatic injury wounds. Many patients recover lost function, including the ability to walk, though weakness may remain in legs.

ANTERIOR CORD SYNDROME

Anterior cord syndrome (also known as anterior artery syndrome) occurs when the front 2/3 of the spinal cord is compressed, often due to decreased blood supply from the anterior spinal artery. The blockage may be caused by surgery to repair an aortic aneurysm, or compression caused by herniated disc, tumor, burst fracture, or a hyperflexion injury (when the head is forced down toward the chest.) The syndrome is characterized by motor weakness and loss of pain and temperature sensation below the level of injury. Because the posterior (rear) region of the cord remains intact, individuals still retain their sense of light touch, vibration, and proprioception (an awareness of the position and movement of the body.) The severity of the motor dysfunction is determined by the level at which the injury occurs. If the blockage impacts the T1-L2 vertebrae, there may also be impaired sexual and bowel and bladder function.

Figure 5A depicts the parts of the body affected by anterior artery syndrome. Figure 5B depicts a cross section of a spinal cord affected by anterior artery syndrome.



Symptoms:

- Sudden and severe back pain
- Weakness or paralysis below the level of injury
- Pain and temperature loss at and below the level of injury
- Sexual dysfunction
- Bowel and bladder dysfunction

Diagnosis:

An MRI can identify the damage to the spinal cord. A clinical examination will also be conducted to evaluate symptoms.

Treatment:

Depending on the cause of the injury, surgery may be needed to repair aortic dissection, or remove bones or fragments that are compressing the spinal cord. Interventions to increase blood flow to the affected area using IV fluids or medications may also be necessary. Physical and occupational therapy will follow acute treatment to help restore function.

POSTERIOR CORD SYNDROME

Posterior cord syndrome, the least common of the spinal cord syndromes, occurs when the back columns of the spinal cord are damaged. External compression of the spinal cord due to a tumor or degenerative disease can cause this syndrome, along with a blockage of the posterior spinal artery or demyelinating disorders such as multiple sclerosis and vitamin B12 deficiency. Because the damage occurs in the part of the cord that controls information about proprioception (an awareness of the position and movement of the body,) vibration, and fine-touch sensation, these functions will be diminished. Depending on the size of the lesion, the injury may also impact spinal tracts controlling motor and autonomic function, causing weakness, spasticity, incontinence, and erectile dysfunction. Most people diagnosed with this syndrome are able to walk but may experience instability and impaired balance as a result of decreased proprioception.

Symptoms:

- Unsteady gait
- Loss of balance
- Clumsiness
- Frequent falls, especially in the dark or with eyes closed

Diagnosis:

Doctors will evaluate neurological function through clinical tests with a focus on sensory impairment; testing balance with eyes closed can help identify this syndrome. An MRI will help assess damage to the spinal cord.

Treatment:

If possible, the underlying cause of the condition should immediately be treated. For vitamin deficiency, supplements may be given. Surgery may be needed to prevent further damage from herniated disks or other sources of external compression. Occupational and physical therapy can help improve balance and coordination.

CONUS MEDULLARIS SYNDROME

This syndrome occurs when the conus medullaris – the tapered end of the spinal cord typically located around the L1 vertebra – is damaged, typically by a herniated disk in the lower thoracic or upper lumbar spine; burst fractures, tumors, or an infection caused by epidural abscess may also cause the condition. Conus medullaris syndrome results when there is compressive damage to the spinal cord from T12-L2. The injury impacts the sacral spinal nerves which originate in the conus (S3-S5) and convey motor and sensory information to the bowel and bladder, lower limbs and buttocks and groin region. Sexual dysfunction, and bladder and bowel impairment are affected by this injury, with lower extremities possibly experiencing mild weakness. Symptoms, including sharp back pain, occur suddenly. Early diagnosis and treatment can improve outcomes.

Symptoms:

- **Severe back pain**
- **Numbness or loss of sensation in the buttocks, groin and upper thighs known as saddle anesthesia**
- **Sexual dysfunction, including impotence**
- **Bowel and bladder dysfunction, including retention or incontinence and reduced anal sphincter reflexes**
- **Mild to moderate weakness in lower limbs**

Diagnosis:

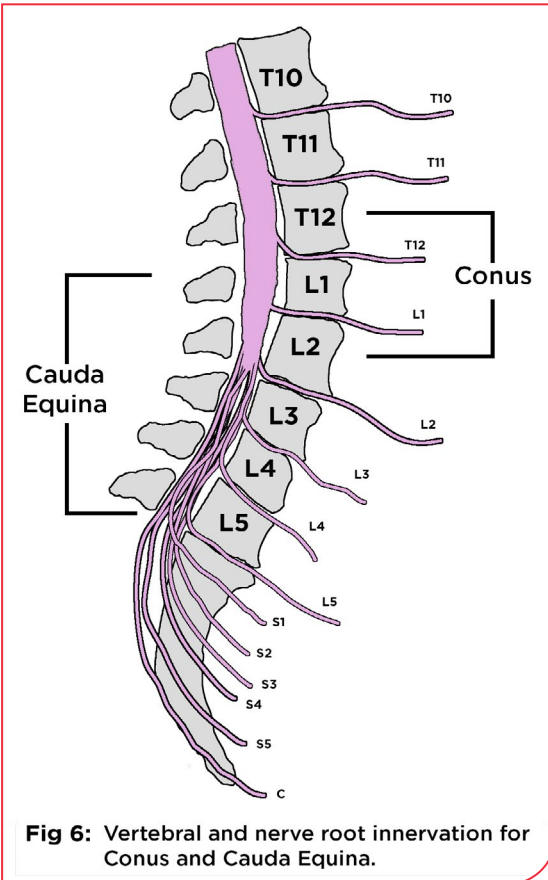
An MRI will help determine damage to the spinal cord. In addition, a neurological examination will help distinguish this injury from the

similarly presenting cauda equina syndrome (see below). The presence of the Babinski reflex – in which the big toe moves upward in response to a sensory test performed on the foot – indicates damage to the descending spinal tract, an upper motor neuron injury associated with conus medullaris syndrome.

Treatment:

Surgery to relieve pressure on the spine is the typical treatment when the syndrome is the result of acute trauma. Physical and occupational therapy may help restore function. Outcomes are improved for this syndrome with early diagnosis.

CAUDA EQUINA SYNDROME



This condition is named for the cluster of nerves resembling a horse's tail that extends from the end of the spinal cord in the lumbar region (L1-L5). These nerves, which communicate with the pelvic organs and lower limbs, can be injured due to trauma or compression. A herniated disk that damages the L3-L5 vertebrae is a common cause of the condition; it may also be the result of a tumor, infection, spinal stenosis, or direct trauma to the area such as from gunshot wounds or a car accident that cause bone fragments to enter the canal. Symptoms, including sharp back

pain, overlap with those of conus medullaris syndrome and can similarly develop rapidly, or progress gradually over time. Because of the location of the injury, muscle weakness and diminished tone will be more present than in conus medullaris; specific deficits will depend on which nerve roots are affected, but can occur on one side of the body, rather than symmetrically.

Symptoms:

- **Bowel and bladder dysfunction, including urinary retention or incontinence**
- **Severe lower back pain**
- **Weakness and flaccid paralysis in lower limbs**
- **Numbness or loss of sensation in the buttocks, groin, and upper thighs known as saddle anesthesia**
- **Sexual dysfunction**

Diagnosis:

An MRI (or CT scan or X-rays) can determine the degree of compression and damage. Doctors will also review patient history and perform a clinical examination to evaluate symptoms.

Treatment:

Surgery is the most common treatment for relieving the compression causing the impairment. Early treatment can increase the chance of regaining function; if untreated, cauda equina syndrome can cause permanent paralysis or bowel and bladder dysfunction.

COMPLETE TRANSVERSE SYNDROME

Complete transverse syndrome occurs when a lesion damages the majority of an entire spinal cord segment at any level. This rare injury can stem from either traumatic or non-traumatic causes, including a violent event that severs the cord, such as a knife attack; bullet; high velocity accidents that cause vertebral fracture–dislocation or stretch the cord’s nerve fibers to the point of total breakage; and blocked arteries that stop the flow of blood to the spinal cord.

Unlike spinal cord syndromes that only partially damage the cord, complete transverse syndrome disrupts communication across all spinal tracts. The result is the loss of all motor and sensory functions below the level of injury.

Figure 7A depicts the parts of the body affected by complete transverse syndrome. Figure 7B depicts a cross section of a spinal cord affected by complete transverse syndrome.

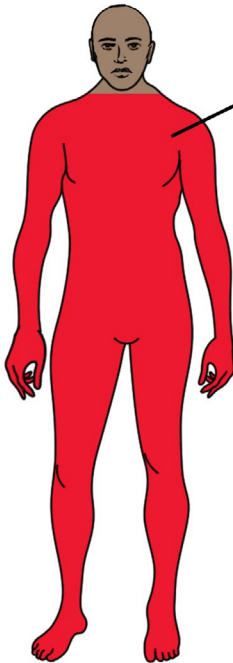
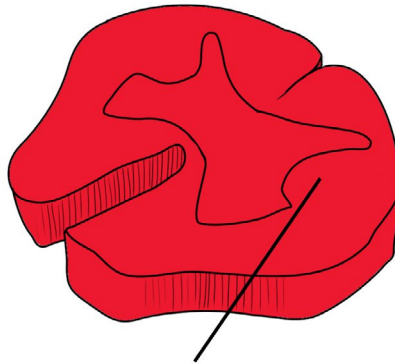


Figure 7A

Complete transverse syndrome is a complete transection of the spinal cord which results in a complete loss of strength and sensation below the level of injury.



Damaged region of spinal cord is depicted in red

Figure 7B

Symptoms:

- Severe back pain or pressure
- Complete loss of movement and sensation below the level of injury
- Loss of bowel and bladder function
- Possible impaired breathing

Diagnosis:

An MRI (or CT scan or X-rays) can determine the degree and location of damage. Doctors will also review patient history and perform a clinical examination to evaluate symptoms.

Treatment:

The severity of this injury will likely require surgery to stabilize the spinal column. Physical and occupational therapy will be needed to help individuals adapt to the paraplegia or quadriplegia caused by the injury.

The loss of function caused by a damaged spinal cord can upend lives and challenge an individual's sense of self. To better adapt to your diagnosis, research the symptoms and impairments specific to your injury. Information on topics ranging from bowel and bladder management to sexual health is available from the National Paralysis Resource Center (NPRC) by contacting an Information Specialist at ChristopherReeve.org/Ask.

Other educational resources can be found online at the Model Systems Knowledge Translation Center for Spinal Cord Injury at <https://msktc.org/SCI>.

Rehabilitation will likely be necessary following initial diagnosis and treatment for most spinal cord syndromes. With help from physical and occupational therapists, identify adaptive equipment and assistive devices that will help compensate for lost function. Canes or walkers may support weakened mobility, while oversized mouse trackball or voice recognition software can help compensate for limited dexterity.

Seek out healthcare professionals who are familiar with spinal cord syndromes, or who have experience with spinal cord injuries. Physiatrists are doctors who specialize in physical medicine and rehabilitation, including conditions that affect the spinal cord. The American Academy of Physical Medicine and Rehabilitation maintains a searchable database of physiatrists across the country. For more information, visit <https://www.aapmr.org>.

In addition, pay attention to mental health. Life changes associated with spinal dysfunction may cause depression. According to the Model Systems Knowledge Translation Center, the estimated rates of depression among people with spinal cord injuries range from 11% to 37%. If you are experiencing symptoms such as changes in appetite or sleep patterns, hopelessness, diminished energy, or a lack of desire to participate in life activities, consult with your physician and seek counseling.

Connecting with others experiencing similar challenges can help foster recovery. The NPRC's Peer & Family Support program offers a national peer-to-peer mentoring program that provides critical emotional support along with local information and resources. The program also offers caregiver to caregiver mentoring.

Sources: Merck Manual, The American Association of Neurological Surgeons, Johns Hopkins Medicine, Shepherd Center, University of Maryland Medical Center, Cleveland Clinic, University of Pittsburgh Medical Center, Department of Neurology at Columbia University Irving Medical Center, Department of Neurobiology and Anatomy at the University of Texas McGovern Medical School, American Academy of Orthopaedic Surgeons, **The Journal of Spinal Cord Medicine**, vol. 30 (3) 2007, The Radiological Society of North America **RadioGraphics**, vol. 38 (4), 2018, **Management of Spinal Cord Injury** by Cynthia Perry Zejdlik, Boston: Jones and Bartlett Publishers, 1992.



We're here to help.

Learn more today!

Christopher & Dana Reeve Foundation

636 Morris Turnpike, Suite 3A

Short Hills, NJ 07078

(800) 539-7309 toll free

(973) 379-2690 phone

ChristopherReeve.org

This publication is supported by the Administration for Community Living (ACL), U.S. Department of Health and Human Services (HHS) as part of a financial assistance award totaling \$10,000,000 with 100 percent funding by ACL/HHS. The contents are those of the author and do not necessarily represent the official views of, nor an endorsement by, ACL/HHS or the U.S. government.